

VASCULAR UPDATE

Vol 3 No 1
November 1998

EDITOR : PHILIP MATLEY
CONTRIBUTORS : PETER JEFFERY & JAMES TUNNCLIFFE

CAREFUL CASE SELECTION THE KEY TO ENDOVASCULAR TREATMENT OF AAA

At the recent European Society of Vascular Surgery meeting in Paris the importance of careful patient selection for possible insertion of aortic stent grafts was emphasised. At least eight highly sophisticated systems for the insertion of bifurcated stent-grafts into aortic aneurysms via the femoral artery are now commercially available and several thousand of these have been inserted worldwide. These represent vast improvements on the initial tube graft systems and have solved most of the technical problems associated with delivery and deployment. Technical success rates are therefore high (>95%) with few complications being reported.

However the chief drawback of endografts for aneurysms (apart from the very high cost of the device) is the propensity for both early and late endoleaks. An "endoleak" implies that the stent graft has failed to exclude the aneurysm from the circulation either because of an error in initial deployment or subsequent changes in the size, shape or position of the aorta, aneurysm sac, iliac arteries or the device itself. These can be demonstrated using CT or colour doppler. Patients with endoleaks remain at risk

of rupture and must be regarded as treatment failures. Ideally late endoleaks should be seen in less than 10-15% of cases but several series have reported rates as high as 30-40%. Chronic endoleaks require further intervention which may be an endovascular procedure such as cuff extension of the graft. Occasionally a formal surgical repair is the only solution.


The key to success is careful patient selection respecting the numerous absolute and relative contra-indications to the procedure. It is estimated that currently only 30-40% of aneurysms fulfil the stringent criteria, but in these patients the procedure will probably be both safe and durable.

The long term outlook is unknown as few patients have been followed up beyond 3 years. There is therefore concern about implanting these devices in patients younger than 75. High surgical risk patients are not necessarily ideal candidates particularly if the anatomy is unfavourable as surgical conversion is extremely dangerous under these circumstances. Such high risk patients are unlikely to survive for more than a short period because of their serious co-morbidities. It is

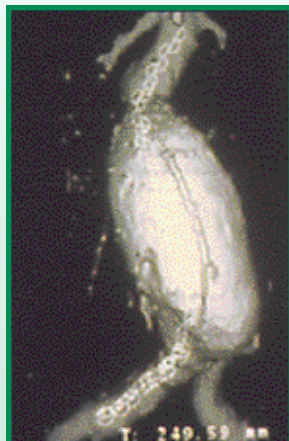
debatable whether such expensive and limited resources should be invested in them unless the aneurysm is symptomatic. Although smaller aneurysms are easier to treat we cannot be certain that they need to be treated at all. Whether placing an endograft into a small aneurysm will be better than waiting until it is larger and more difficult to treat remains uncertain and is the subject of an on-going study.

Although several surgeons and non-surgeons now have the necessary catheter and endovascular skills to implant these devices, these management decisions are best made by vascular specialists who have considerable experience in the management of abdominal aortic aneurysms and who can address all the aspects involved and thus provide comprehensive management of the patient.

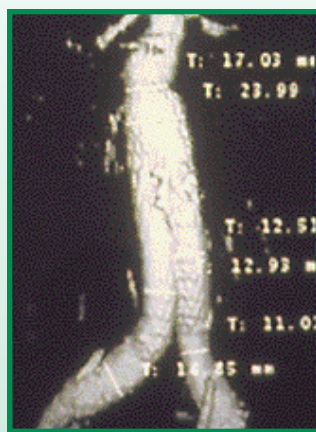
Our team of three vascular surgeons has the necessary experience in aneurysm management to make these evaluations and decisions and, following recent training in Europe, is now able to offer endovascular aneurysm repair as part of our overall treatment of this challenging problem.



AneuRx Stent Graft
in situ



Preoperative Spiral CT of
AAA with 3D reconstruction



Postoperative Spiral CT with
3D reconstruction



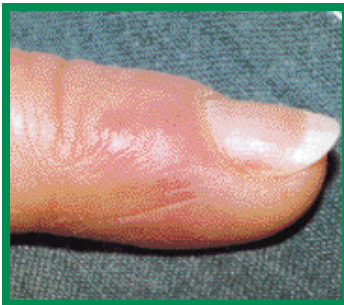Post-insertion angiogram of
AneuRx device

Chilblains

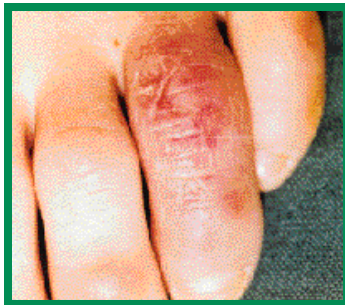This common benign vascular cutaneous syndrome caused by exposure to cold, humid conditions is poorly understood. Acute chilblains appear as extremely painful and often symmetrical erythematous or erythro-cyanotic plaques or papules with shiny tense overlying skin involving the fingers or toes. As the temperature rises they tend to become intensely pruritic and resolve over 3-4 weeks. They may or may not be associated with Raynaud's Phenomenon. Chronic chilblains persist throughout winter as ulcerated painful lesions usually on the toes. They may be associated with SLE, polyarteritis, anorexia nervosa or chronic myeloid leukaemia.

Peripheral pulses are usually easily palpable and laboratory tests are helpful only in excluding other systemic diseases. The differential diagnosis includes systemic vasculitis and the "blue toe syndrome" from athero-embolism or malignancy.

Apart from the avoidance of cold and the application of vaseline the mainstay of treatment is nifedipine (Adalat) which appears to have vaso-dilatory, anti-inflammatory and platelet anti-aggregating properties. Intramuscular vitamin K appears to improve resolution as does phototherapy with ultraviolet light. Occasional cases with severe necrosis may require an endoscopic sympathectomy.



Erythematous Plaque



Chilblains on the toes

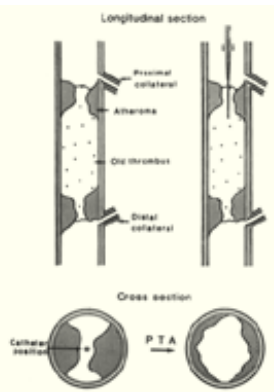
Congenital Vascular Malformations and Hemangiomas

These are among the most common of congenital abnormalities. Hemangiomas are biologically active, with a proliferative growth phase, while vascular malformations are biologically inert. Hemangiomas are thus true endothelial tumors, and may involute, or grow disproportionately, unlike the malformations, which remain proportionate in size with growth of the child. Hemangiomas are more common in girls than in boys (3:1). They usually appear a few weeks after birth, and grow disproportionately quickly. Superficial lesions are strawberry pigmented, and grow for up to 18 months before involution. Regression is common (70-90%), but usually leaves skin changes. Vascular malformations are always present at birth, but may not be obvious initially. Pigmentation usually deepens with age. Nodularity is uncommon in childhood, but may develop in adulthood. Regression never occurs. Hemangiomas may be differentiated from vascular malformations on history and examination. Each has classical features

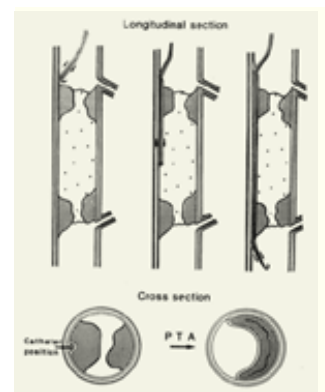
on investigation. Differentiation is important, as treatments differ depending on lesion type. Hemangiomas are usually allowed to involute naturally, unless they threaten vital structures (obstruction of visual axis or oral or digestive tract, airway, bilateral auditory canals, congenitive cardiac failure, or platelet consumption syndromes) or endanger life. Bleeding, ulceration, or potential for facial disfigurement are relative indications for intervention. Treatment may require surgical excision, sclerotherapy, embolisation, laser coagulation and radiotherapy, either alone or in combination. Hemangiomas may appear as part of a syndrome with other congenital abnormalities, such as sternal clefts or neurological defects. Vascular malformations that need treatment are best treated by Laser Photocoagulation, with good results. Vascular malformations may also occur as part of several syndromes, such as the Klippel-Trenaunay or Sturge-Weber syndromes. Prognosis in these cases depends on the associated anomalies.

SUBINTIMAL ANGIOPLASTY

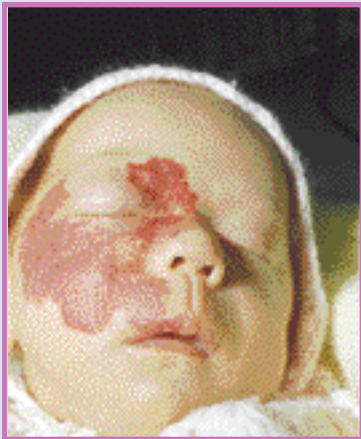Intraluminal angioplasty has been used successfully in the lower limb for years but until recently creating an arterial dissection by entering the subintimal plane with a guidewire or catheter was considered to be a complication that demanded aborting the procedure. It is now recognised that entering and dilating this plane using a balloon catheter may be preferable to an "in the lumen" technique, particularly for long occlusions of the femoro-popliteal and crural vessels. These artificially created channels in the arterial wall assume a round tubular configuration when appropriately dilated using a balloon as long as blood continues to flow. The wall of this plane is smooth and non-thrombogenic unlike the fractured dilated atherosclerotic plaque left behind after standard angioplasty. This may account for the poor results of balloon angioplasty in long occlusions and the improved results in this situation with a subintimal technique. Excellent results have been reported from the Leicester Royal Infirmary where the technique was first developed. Currently subintimal angioplasty is attempted in all their patients with critical limb ischaemia. Surgical bypass is considered only if this is unsuccessful. This is now being performed at Kingsbury Hospital with gratifying results.



Classical angioplasty involves the contraluminal insertion of a guidewire followed by a balloon over the wire to dilate the lesion



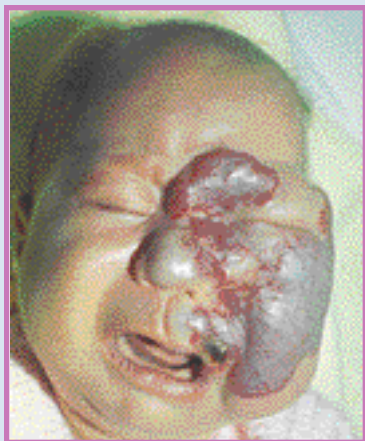The subintimal plane is entered by the guidewire which is re-entered into the vessel lumen below the occlusion. The new lumen is then dilated with a balloon.



Facial hemangioma at birth

All congenital vascular abnormalities should be assessed by a Paediatrician and Surgeon.

Treatment may be multidisciplinary, and usually produces good results.



Hemangioma 4 months of age

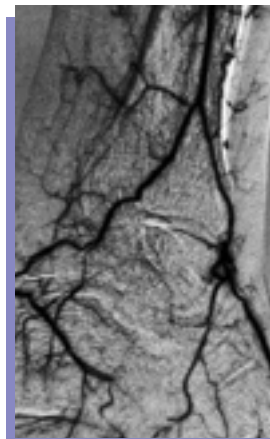
When are patients with Critical Limb Ischaemia “Inoperable”?

It is clearly important to define which patients with critical limb ischaemia are inoperable to avoid unnecessary surgical or endovascular interventions which cannot benefit the patient. Although many studies have shown that distal bypass surgery is cheaper than amputation, a bypass followed by an amputation is far more expensive. Since the proximal vessels can usually be easily treated, inoperability usually refers to the absence of a distal artery which can be used for the anastomosis of a suitable graft with a reasonable chance of a successful outcome. The European Consensus Statement on Critical Limb Ischaemia defines a successful outcome as a 25% chance of a 1 year limb salvage. The absence of a crural vessel on angiography does not necessarily indicate inoperability as a suitable vessel can often be demonstrated using pulse generated runoff (PGR) together with colour flow doppler or even a surgical exploration with the introduction of radiographic contrast directly into the vessel. This vessel may even be a foot artery such as the dor-

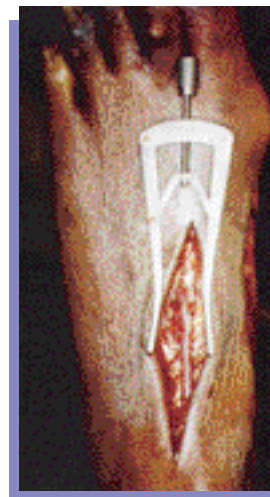salis pedis, medial or lateral plantar artery as several recent studies have shown excellent long term patency and limb salvage rates for bypasses performed to these vessels.

A good quality vein, whether long saphenous, short saphenous or arm vein is usually a pre-requisite for a successful bypass and in its absence a primary amputation may have to be considered rather than resorting to a prosthetic graft. A colour doppler examination is essential to determine the availability and quality of the vein.

Finally the extent of necrosis or gangrene in the foot may declare the situation to be inoperable regardless of the arterial anatomy. Large heel ulcers with extensive necrosis seldom heal after bypass surgery and insufficient soft tissue to permit healing of trans-metatarsal amputation demands at least a below-knee ablation. Inoperability in Critical Limb Ischaemia is determined by the absence of a suitable distal vessel, the absence of an adequate vein and the extent of necrosis. In most series 5-8% of patients with CLI are truly inoperable and should be offered primary amputation.



Selective digital diagram showing the distal peroneal artery perfusing the dorsal pedal and plantar arteries via collaterals



Vein bypass to dorsalis pedis artery for CLI

LIPID REDUCTION THERAPY IN PVD

There is firm evidence for lipid reduction in patients with symptomatic arterial disease. This is based on large randomised trials and cost-benefit analyses. Patients with symptomatic PVD have an annual incidence of myocardial infarction of at least 5% in spite of anti-platelet therapy. One third of these attacks will be fatal.

Although high levels of LDL-cholesterol promote atherogenesis, the benefit of statins is probably more related to reductions in thrombogenicity (particu-

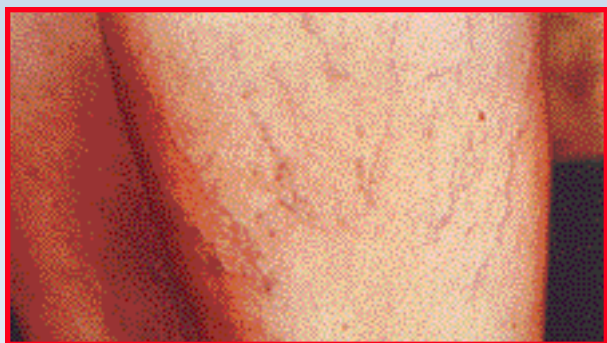
larly lower levels of factor VII and IX) and blood viscosity than to actual reductions in LDL levels. Three large randomised trials of simvastatin and pravastatin have now demonstrated significant reductions in major coronary artery events, cardiovascular and total mortality in such patients. The fibrates have a relatively small effect on LDL but greater effects on VLDL, triglyceride and fibrinogen all of which are important in atherogenesis and thrombosis. The MRC LEADER study is currently examining their possible role in patients with symp-

tomatic PVD. The results are eagerly awaited.

There is, however no conclusive evidence that lipid reduction improves claudication distance or graft patency as no large double-blind, placebo-controlled randomised trials have examined this question. In spite of this our practice continues to be to recommend aggressive control of cholesterol levels greater than 5.5 by appropriate dietary management and careful use of lipid lowering agents.

ADJUSTABLE PULSE WIDTH LASERS

A major advance in varicose vein treatment



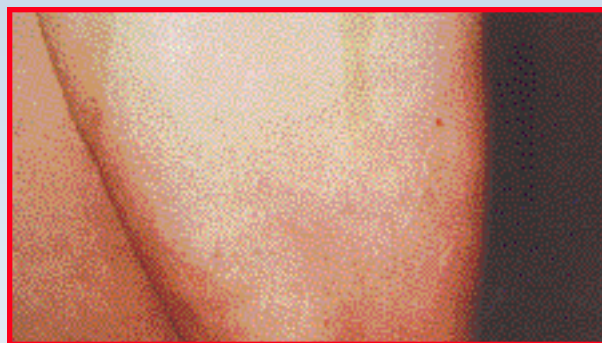
Typical spider veins suitable for the Aura Laser

A new generation adjustable pulse width vascular laser has been installed at the Claremont Leg Vein and Leg Ulcer Clinic. The ability to alter pulse-width to target vessel size makes it an extremely versatile and effective laser suitable for the treatment of a wide range of laser responsive cutaneous vascular lesions such as small leg veins, facial veins and port-wine stains.

The Laserscope Aura is able to

target small well defined superficial leg telangiectasia (spider or thread veins) of less than 1.5mm in diameter. Several treatments spaced at monthly intervals are required. Like all lasers it works best in fairer, non tanned skin.

The Laserscope Aura now forms an important part of the Claremont Leg Vein and Leg Ulcer Clinic, a multi-disciplinary team that encompasses vascular surgery, dermatol-



After treatment with the Aura Laser

ogy, plastic surgery, laser medicine and nursing. With access to sophisticated diagnostic tools and a wealth of experience in the management of venous disease and leg ulcers, the clinic is able to offer a comprehensive service for all levels of severity of leg vein disease.

Initial appointments for evaluation can be arranged by phoning 683 3893 or 683 4580 / 683 3048.

SPIRAL CT ANGIOGRAPHY

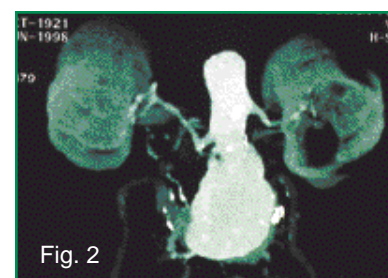
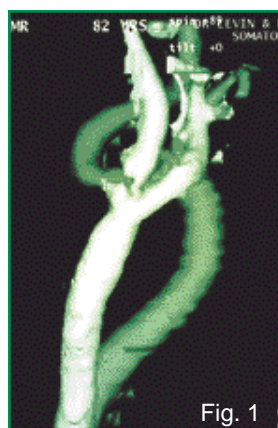
Spiral CT Angiography is a new method of vascular imaging that produces spectacular multi-planar and 3 dimensional images of vessels. Rapid scanning (while iodinated contrast is given intravenously) allows acquisition of imaging data during maximum opacification phases. Subsequent image enhancement including 3D reconstruction is possible using sophisticated software.

Carotid bifurcation disease is well depicted using this modality, the accuracy being similar to MRA (magnetic resonance angiography) without many of the pitfalls of MRA. Conventional angiography, with a small but real risk of complications, remains the gold standard but it is anticipated that it will be gradually replaced by Spiral CTA. Fig. 1 illustrates a case of significant internal carotid artery stenosis. The arteries can be viewed from any angle to provide the surgeon with an accurate pre-operative visual representation.

A variety of aortic abnormalities may be examined. Spiral CTA provides excellent anatomical information for planning the treatment of aneurysms and has become the essential investigation prior to stent-grafting of abdominal aortic aneurysms, as demonstrated in Fig 2. It is the investigation of choice in aortic dissection and the most accurate non-invasive imaging technique for assessment of renal artery stenosis. Peripheral arterial abnormal-

ities and intracranial arterial lesions are also well demonstrated. In some centres spiral CTA is the initial investigation of pulmonary embolism.

Although conventional angiography will probably remain the gold standard, spiral CTA is less invasive, less expensive, easier to perform and quicker than conventional angiography. It is certainly a major advance in vascular imaging. It is now available in several hospitals in Cape Town.



ABOVE: Spiral CTA of AAA

LEFT: Spiral CTA of Internal Carotid Stenosis

Look for us on the web

Caine and Partners now has it's own website at <http://www.surgcare.co.za>

This website is currently under construction but when completed will have all the previous editions of both Vascular Update and GIT Update as well as lots of useful and interesting information on many aspects of our surgical practice. For any comments on Vascular Update or any other queries e-mail us at surgeons@surgcare.co.za