

VASCULAR UPDATE

EDITOR: MARTIN FORLEE

CONTRIBUTORS: PHILIP MATLEY, JAMES TUNNICLIFFE, MARTIN FORLEE

RADIOFREQUENCY ABLATION FOR VARICOSE VEINS (RFA)

Many people consider varicose veins to be simply a cosmetic issue, so they delay treatment or avoid it completely. Untreated varicose veins can progress to a more serious form of venous disease called chronic venous insufficiency, which can present with signs and symptoms such as pain, ankle swelling, fatigue of the legs, skin damage and ulcers. Modern technology and newer techniques have allowed the treatment of varicose veins to become minimally invasive.

Is RFA better than standard surgery ?

RFA avoids the cut in the groin or behind the knee and the ligation and stripping of the truncal vein. The main advantage of RFA is in the 1st two weeks post surgery where there is less bruising, less pain and earlier return to normal activity (like driving) and earlier return to work. In the long term an excellent cosmetic outcome can be expected from either technique. There is a similar risk of recurrence following either procedure. It is also possible to perform this procedure as an office procedure, thereby avoiding hospital admission.

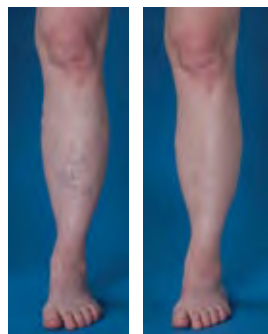Is everyone with varicose veins able to have RFA ?

No. People with large, tortuous veins are not suitable. Recurrent varicose veins after previous surgery

are often unsuitable as are very superficial veins. About 70% of people with varicose veins can be treated with RFA.

Is RFA all I need for my Veins ?

RFA will treat the major truncal veins, including the GSV, anterior thigh veins and SSV. It is, however, usually necessary to treat the branch varicosities with hook phlebectomy or foam sclerotherapy.



BEFORE and AFTER

Is there a downside to RFA ?

RFA uses special catheters as well as ultrasound imaging during the operation. This leads to increased costs compared to standard surgical treatment.

Why do some surgeons not offer RFA ?

There may be many reasons. Some surgeons may not have been trained

WHAT IS RFA ?

Radiofrequency ablation is a newer, minimally invasive technique to treat varicose veins. Heat generated from high frequency alternating current (300-500 kHz) is used to destroy the vein, thus abolishing flow and preventing pressure being transmitted to the veins below.



to use VNUS or do not have ultrasound skills. Certain medical aids do not pay for radiofrequency ablation.

Are there any complications associated with RFA ?

There is a small risk of deep vein thrombosis (DVT) as with all treatments for varicose veins. Some patients may experience an odd sensation or sensitivity in the thigh.


WHAT DOES THE PROCEDURE INVOLVE ?



The greater saphenous or short saphenous vein is punctured percutaneously using duplex ultrasound control. The radiofrequency (VNUS®) catheter is placed up through the diseased vein and positioned approximately 2 cm from the junction to avoid damage to the deep system.



A layer of fluid is injected along the entire course of the vein (tumescant anaesthesia). This fluid has 3 functions: 1) it contains local anaesthetic to provide anaesthesia, 2) acts as heat sump and absorbs heat to prevent damage to surrounding tissue and 3) compresses vein to increase contact with the catheter



The catheter is then activated. A 7cm segment is treated over a 20 second treatment cycle. The vein is heated up to 120°C. The catheter is moved down and the next segment treated. It takes 3-5 minutes to treat a 45 cm length of vein. The operation can be performed under local, general or spinal anaesthetic.

CONGENITAL VASCULAR MALFORMATIONS (CVM)

CVM encompasses vascular tumours and congenital vascular malformations

“Birthmarks” may be a CVM or a haemangioma. Correct diagnosis of the lesion will allow reassurance to the parents, or correct investigation prior to further management.

Venous malformation (VM) is the most common form of CVM. VM presents at birth as an inborn vascular defect and never disappears or regresses spontaneously through the rest of life; it will continue to grow slowly at a rate that is proportional to the growth rate of the body.

In contrast, Haemangioma is **not** a vascular malformation but one of the vascular tumours originating from the endothelial cells; it develops after birth mostly in the infantile/neonatal period with a distinctive growth cycle: a proliferation phase of early rapid growth followed by an involutional phase of slow regression. Haemangiomas may enlarge (sometimes dramatically) after birth, but will usually regress after age 5. They only require

treatment if they are causing visual obstruction, or feeding and breathing difficulties if close to the airway.

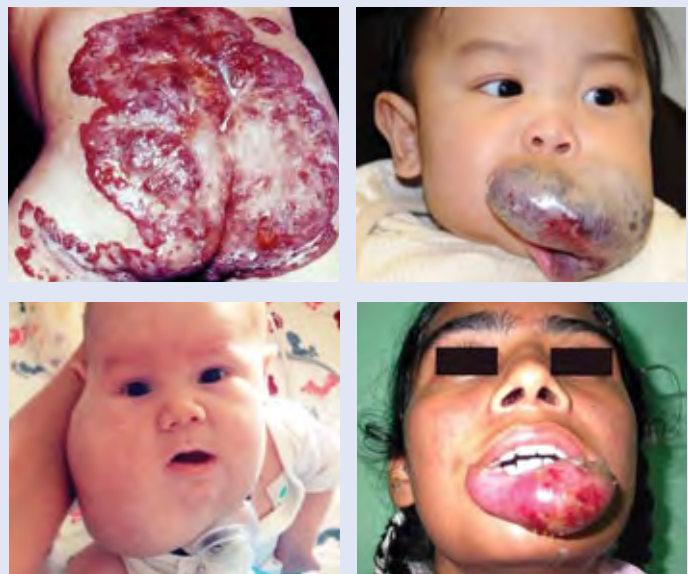Appropriate diagnosis and assessment of vascular malformations can be made based on clinical presentation and a proper combination of basic non-invasive studies. Diagnosis is usually confirmed by duplex ultrasound, with MRI being reserved for deeper or more extensive lesions which cannot be visualised adequately with duplex. Scintigraphy may assist in diagnosing large VM's, particularly in the limbs. Angiography is usually reserved for therapeutic planning and treatment.

Management may be by endovascular embolization, surgical excision, or a combination of these modalities. Birthmarks which are cosmetically unsightly but which would cause worse cosmetic upset if excised may be managed with laser eradication, or tattooing to match the normal skin colour.

The modern classification of Vascular Malformations is based on embryological and pathological findings.

Tumours	Vascular malformation	
	Simple	Combined
Haemangioma	Capillary Malformation (CM) Lymphatic Malformation (LM)	CVM CVLM
Other Tumours	Venous Malformation (VM) Arterio-Venous Malformation (AVM)	LVM CAVM CLAVM

ISSVA Classification of vascular anomalies, 1996, Rome, Italy

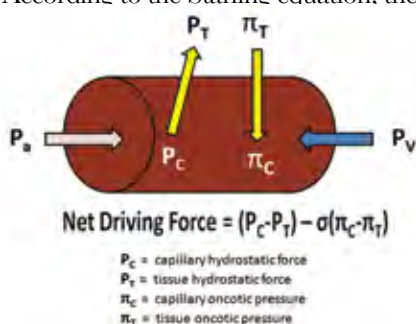


Clockwise from top left: Haemangioma (strawberry naevus), Venous Malformation, Lymphatic Malformation AV malformation

WHY DO GIRAFFES NOT GET OEDEMA?

Ernest Starling first identified the forces that regulate transcapillary fluid balance. Raised capillary hydrostatic pressure (P_C) and tissue oncotic pressure (π_T), as well as decreased capillary oncotic pressure (π_C) and low tissue interstitial pressure (P_T) will promote filtration (oedema).

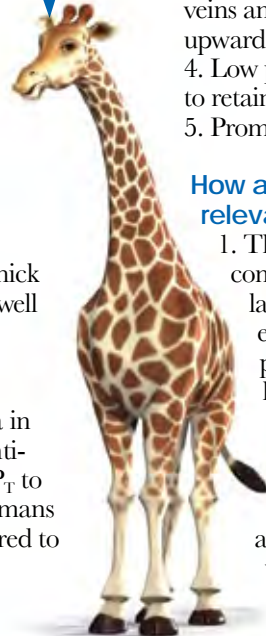
The pressure in the foot of a standing giraffe reaches 250mmHg in the artery and up to 150 mmHg in the vein. According to the Starling equation, the



legs of a giraffe have a net filtration pressure of 88-150 mmHg, suggesting that a giraffe should suffer massive oedema in its feet in an upright, stationary position.

Features that prevent oedema in the giraffe

1. High resistance flow in thick walled arterioles keeps P_V well below P_a , hence capillary hydrostatic pressure (P_C) remains low
2. Very tight skin and fascia in the lower legs acts as an ‘anti-gravity suit’ which allows P_T to be much higher than in humans (average 44 mmHg compared to man where it is 0 mmHg)
3. Very effective muscle



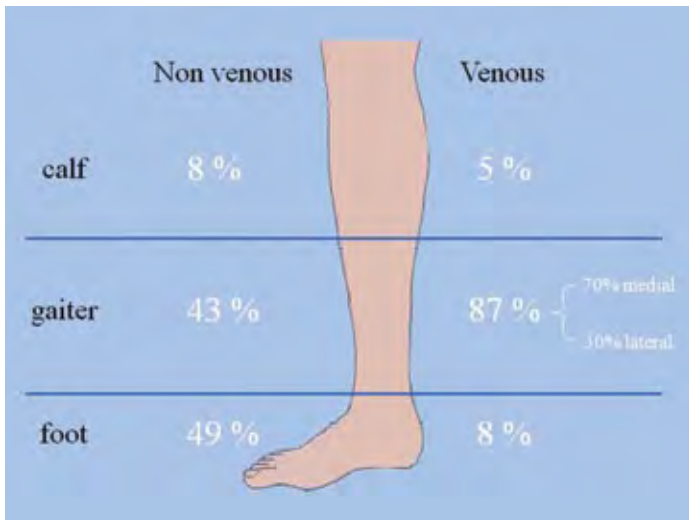
- pump mechanism with one-way valves in veins and lymphatics helps propel blood upwards against gravity (lowers P_V).
4. Low permeability capillary membranes to retain intravascular protein (π_C)
 5. Prominent lymphatic system

How are these observations relevant to the Vascular patient?

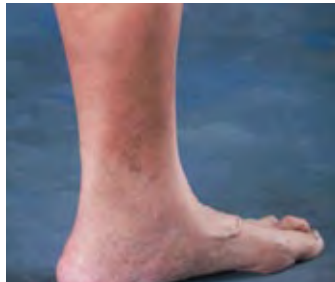1. This explains why graduated elastic compression stockings and the multi-layered compression bandages are effective and essential in managing patients with oedema and venous hypertension. The increase in P_T decreases filtration and promotes resorption of fluid in the tissues.
2. As in the giraffe, the calf muscle pump in man also plays an important role in decreasing venous pressure (hence lowering P_C)...therefore keep walking!

CLINICAL FEATURES OF A VENOUS STASIS ULCER

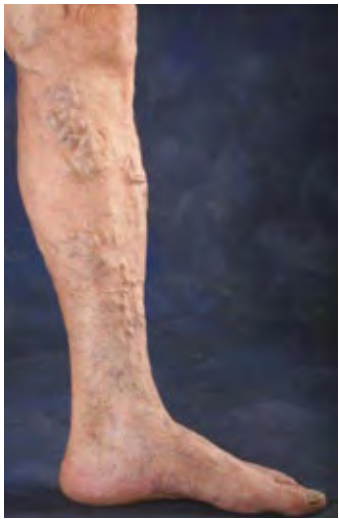Venous stasis ulcers account for 60-70% of lower limb ulcers. Classical features include:



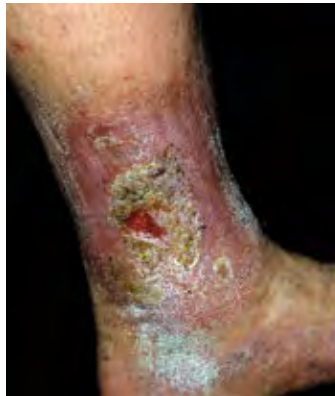Location: the majority occur in the area from the midcalf to the ankle known as the gaiter area. Most are medial. Ulcers presenting on the foot or above the mid calf are less likely to be venous in aetiology



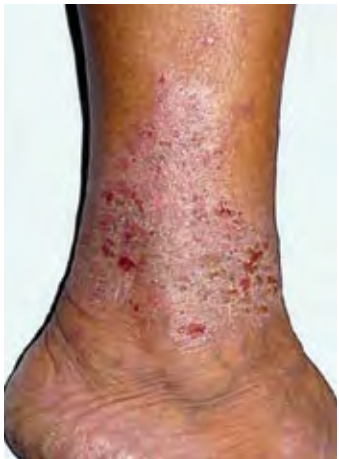Hyperpigmentation: extravasation of red blood cells into the soft tissue results in deposition of haemosiderin in macrophages that stimulate melanin.



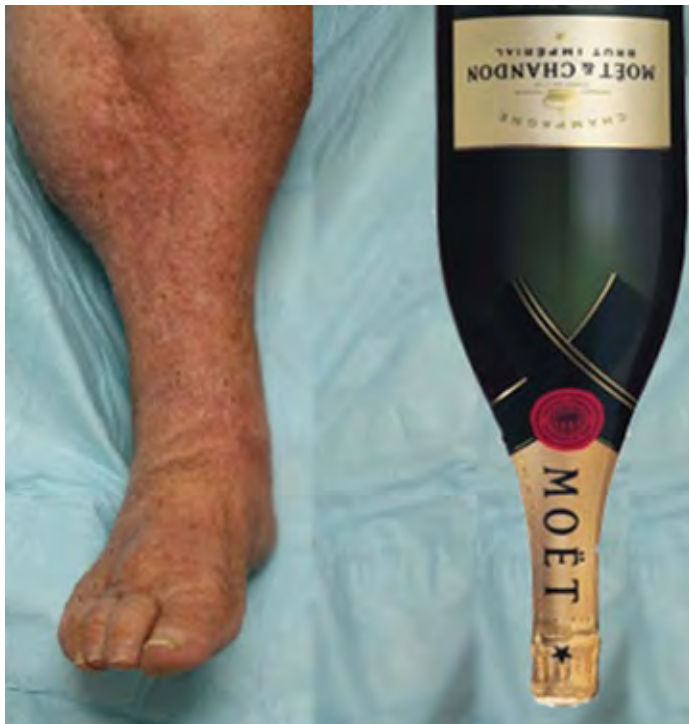Varicose Veins



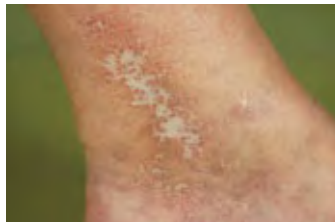Appearance: Venous ulcers may be single or multiple and can range in size from small to circumferential. They tend to be irregularly shaped, are generally shallow, and rarely extend to muscle, fascia or bone. There may be red granulation tissue or yellow fibrinous exudates on the ulcer bed; black necrotic tissue is rarely seen.



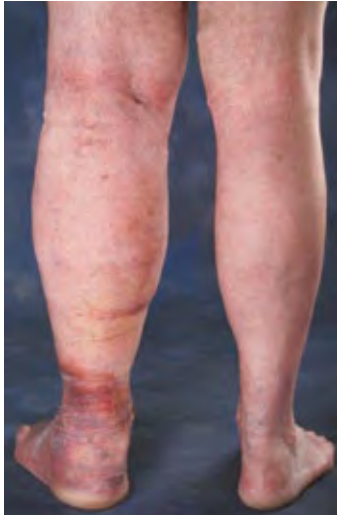Venous eczema (erythema, scaling, weeping, itching) is common.



Lipodermatosclerosis: this is a chronic fibrosing process of the dermis and subcutaneous tissue related to venous insufficiency, resulting in firm and very indurated skin. In its late stages, chronic lipodermatosclerosis alters the shape of the leg, making it look like an inverted champagne bottle—where the proximal leg swells and the distal leg constricts due to loss of subcutaneous fat and fibrosis.



Atrophie blanche is a type of scar arising on the lower leg. It is characterized by star shaped, polyangular white atrophic plaques. It is non-specific and is mostly associated with venous hypertension, diabetic vascular disease and livedoid vasculitis.



Pitting oedema is often present and may pre-date the ulcer.

PELVIC CONGESTION SYNDROME



Illustration by The Real Deal Content 0826293570

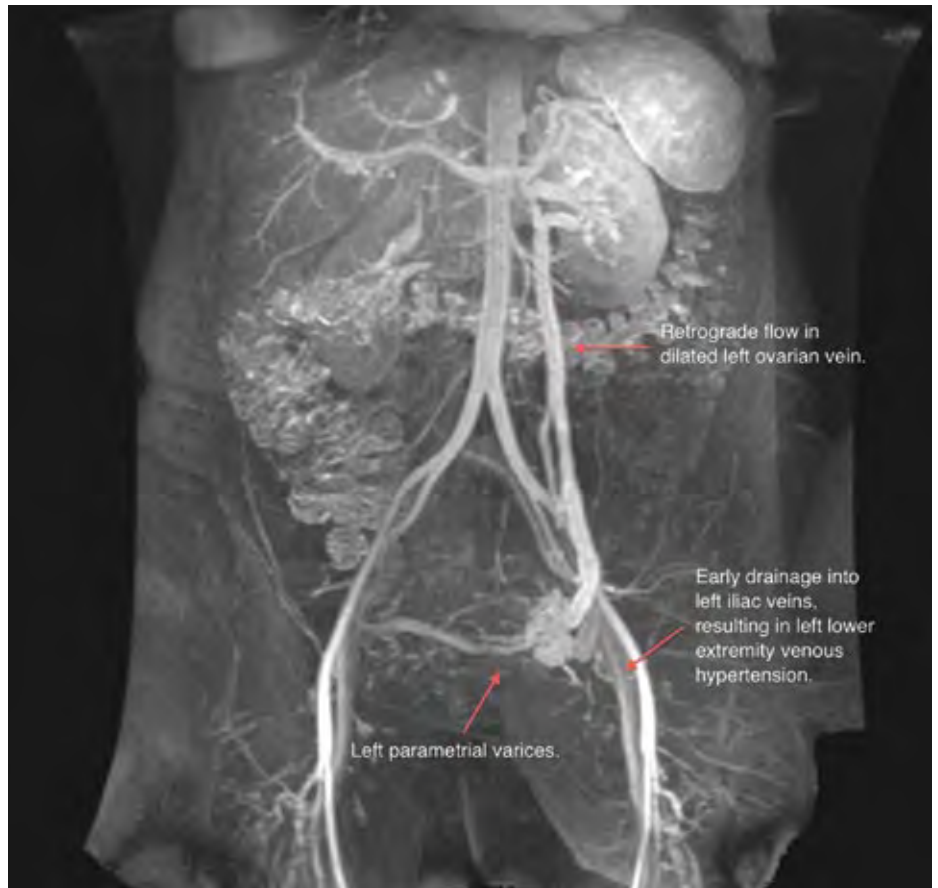
The pelvic veins, like the veins in the lower limb may suffer from abnormal valve function leading to venous hypertension. Large, tortuous and congested veins develop throughout the pelvis. The chief points of origin are the ovarian veins and the internal iliac veins. Should these abnormal pelvic veins communicate directly with the superficial veins of the leg, unusual collections of varicose veins can result. Typically these are associated with discomfort pre-menstrually and after intercourse and can be recognized by experienced vascular surgeons. Dealing with the incompetent pelvic veins is very important to prevent recurrence of the varicose veins.

PCS is an important cause of chronic pelvic pain. However, all such patients require a thorough gynaecological assessment in addition to any specific vascular examination. Typically the pain is dull but severe and may be aggravated at the end of the day or by prolonged standing or sitting. It may be worse before menses or after intercourse but is usually not cyclical.

The diagnosis is suspected when patients present with pelvic pain of undetermined origin or varicose veins, which on duplex scan, appear to arise from within the pelvis. Large tortuous pelvic veins are often noted on a vaginal ultrasound scan.

To confirm the diagnosis, most patients will require CT or MR venography, which are able to demonstrate the very enlarged tortuous veins (particularly the ovarian and internal iliac veins). To plan invasive treatment, pelvic venography is definitive. Investigations performed in the supine position (including laparoscopy) may be falsely negative.

Although some patients benefit from hormone therapy or NSAIDs, modern treatment of this syndrome usually requires interruption of the abnormal pelvic veins and this can usually be achieved using an endovascular technique. The results (in terms of pelvic pain and varicose veins) are particularly good if the problem is confined to the



MR Venography

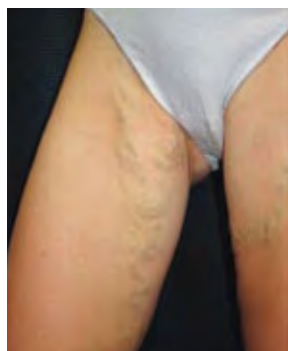ovarian veins, which are very suitable for embolisation.

The procedure is performed as a day-case under local anaesthesia. If significant lower limb varicose veins are to be dealt with at the same time a general anaesthetic may be required. The internal jugular or femoral vein is punctured under ultrasound control

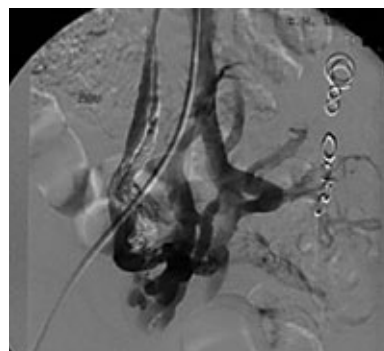
and a thin catheter manipulated through the vena cava using screening to selectively cannulate the abnormal ovarian veins. Several coils are then introduced along the course of the dilated ovarian veins in order to occlude them. A similar technique can be used to deal with the internal iliac veins although various sclerosants are usually preferred rather than coils.

Although embolisation induces thrombosis, this is usually asymptomatic and not associated with pulmonary embolism. Migration of the coils is extremely rare as they are considerably larger than the veins into which they are placed.

In patients with chronic pelvic pain in whom the diagnostic studies are convincing, embolisation is associated with a high chance of clinical success. ■



Typical varicose veins associated with pelvic vein incompetence



Dilated right ovarian and pelvic veins. The Left ovarian vein has been embolised using coils.